

Locally Advanced and Aggressive Thyroid Cancer


World Congress on Thyroid Cancer
Toronto July 2013

Martha Zeiger MD

**Professor of Surgery, Oncology, Cellular and Molecular
Medicine**

Johns Hopkins University School of Medicine

Department of Surgery



Panelists:

Douglas Ball MD, Johns Hopkins University

Rosella Elisei MD, University of Pisa

Patrick Gullane MD, University of Toronto

Thomas McCaffrey MD PhD, Moffitt Cancer

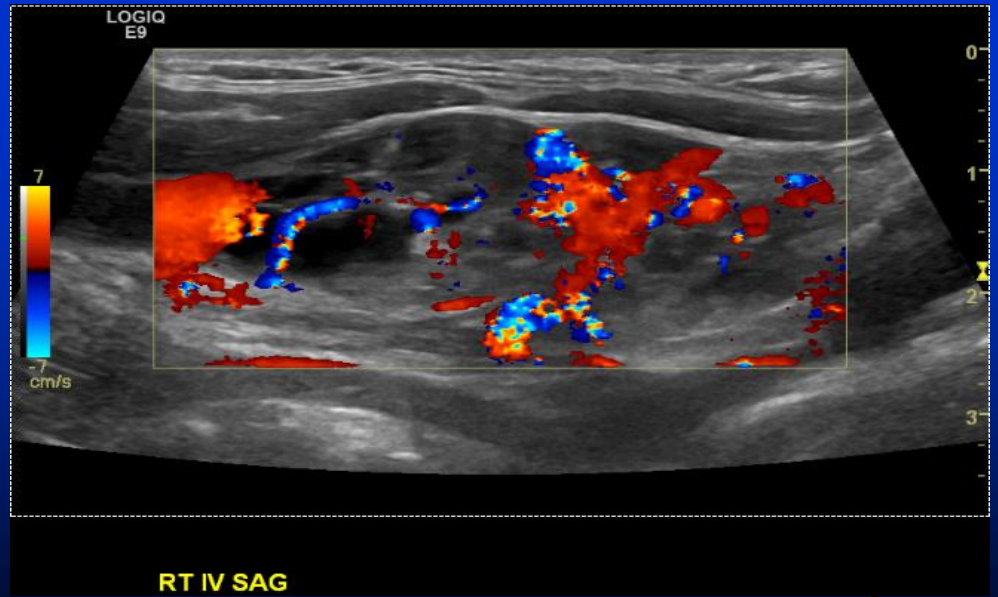
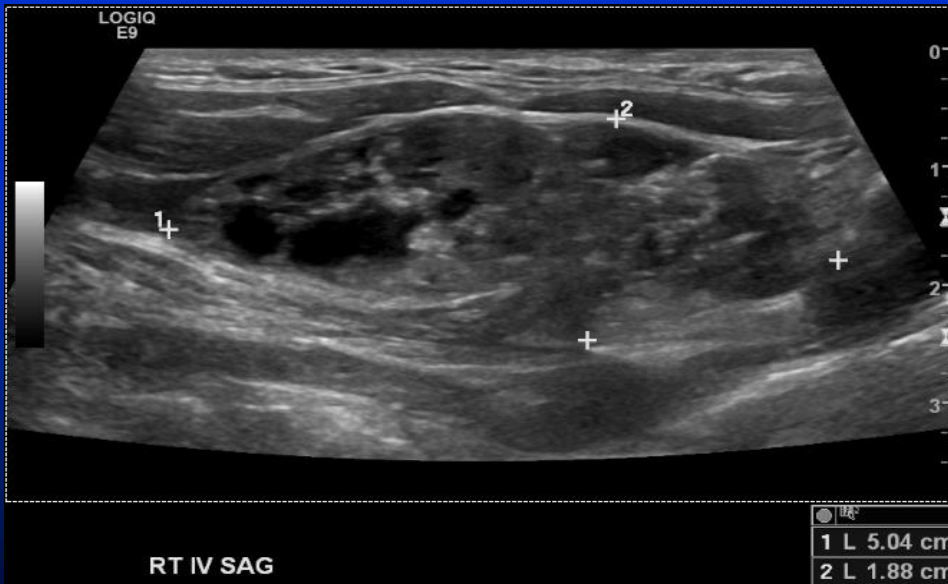
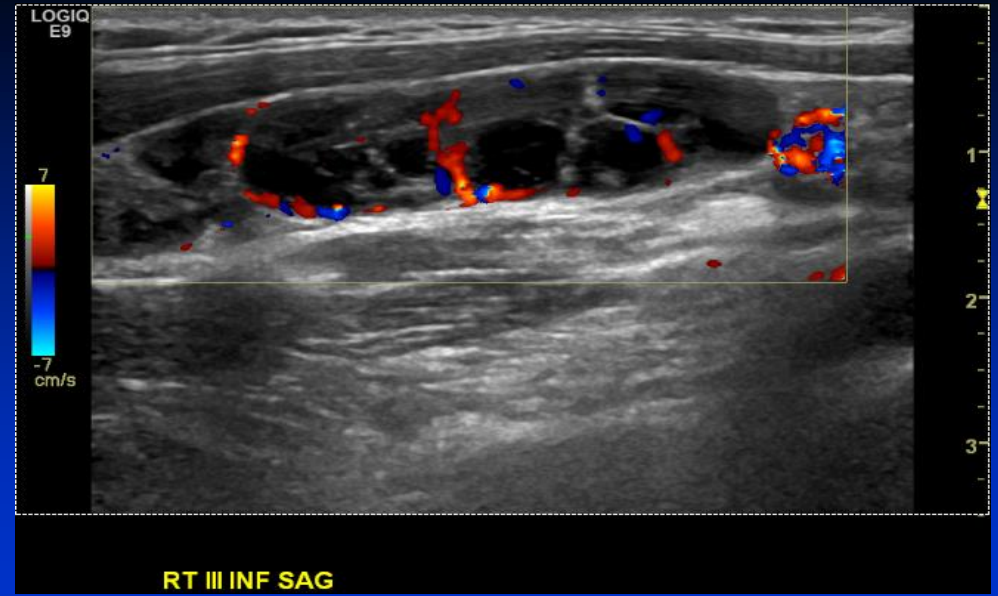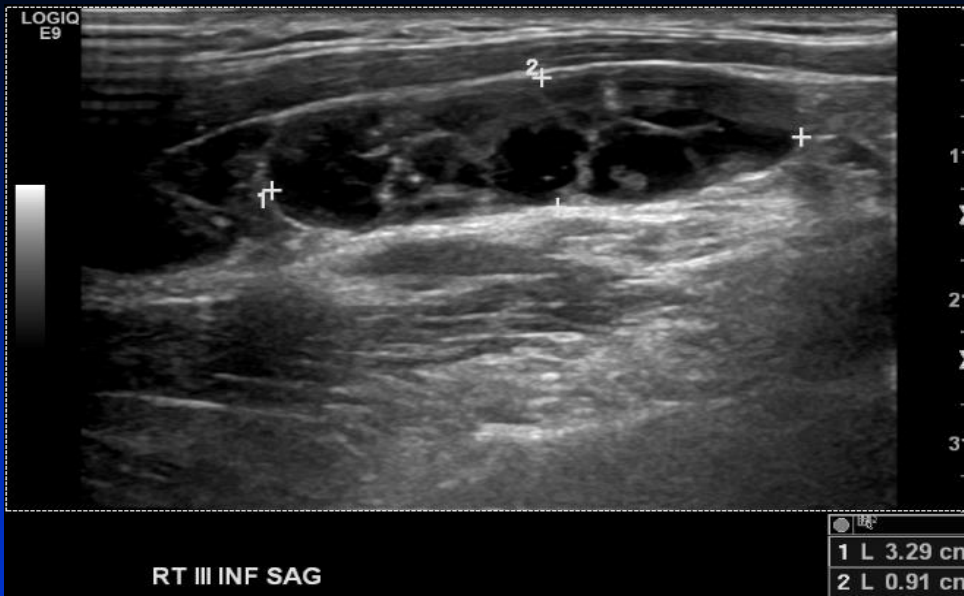Richard Tsang MD, University of Toronto

Case #1

44 female lawyer presents with a 5 yr history of complaints of fatigue, hair loss, night sweats, palpitations, weight gain, decreased libido. Convinced her PCP to refer her to an endocrinologist who ordered a neck ultrasound. This showed a 0.9cm right suspicious thyroid nodule with calcifications.

1st FNA showed Hashimoto's thyroiditis; 2nd FNA showed PTC. Ultrasound also showed suspicious lymphadenopathy. Denied FH of thyroid cancer or irradiation.

Ultrasound at JHU showed several right neck nodes at Levels III-IV mixed solid-cystic lymph nodes with micro-calcifications 1.7-5.0 cm in size; left neck with no suspicious nodes. FNA right Level IV: PTC



July 13, 2013

Questions: Case # 1

1. When do you obtain a neck ultrasound to look for lymphadenopathy if you see a patient with known papillary thyroid cancer (size cutoff/all patients?)
2. When do you order a neck CT scan?
3. Do you always require an FNA of a suspicious lateral lymph node before performing a lateral neck dissection?
4. How do you address the central neck; do you always perform a bilateral CLND?
5. How do you handle the inferior parathyroid glands, especially with matted, bulky lymphadenopathy?

The patient underwent a total thyroidectomy, bilateral central lymph node dissection, right modified radical neck dissection, parathyroid implantation right inferior parathyroid gland

Tumor 1.1 cm with lymphocytic thyroiditis; 15/65 total nodes positive; T1bN1bMx

Questions: Case # 1

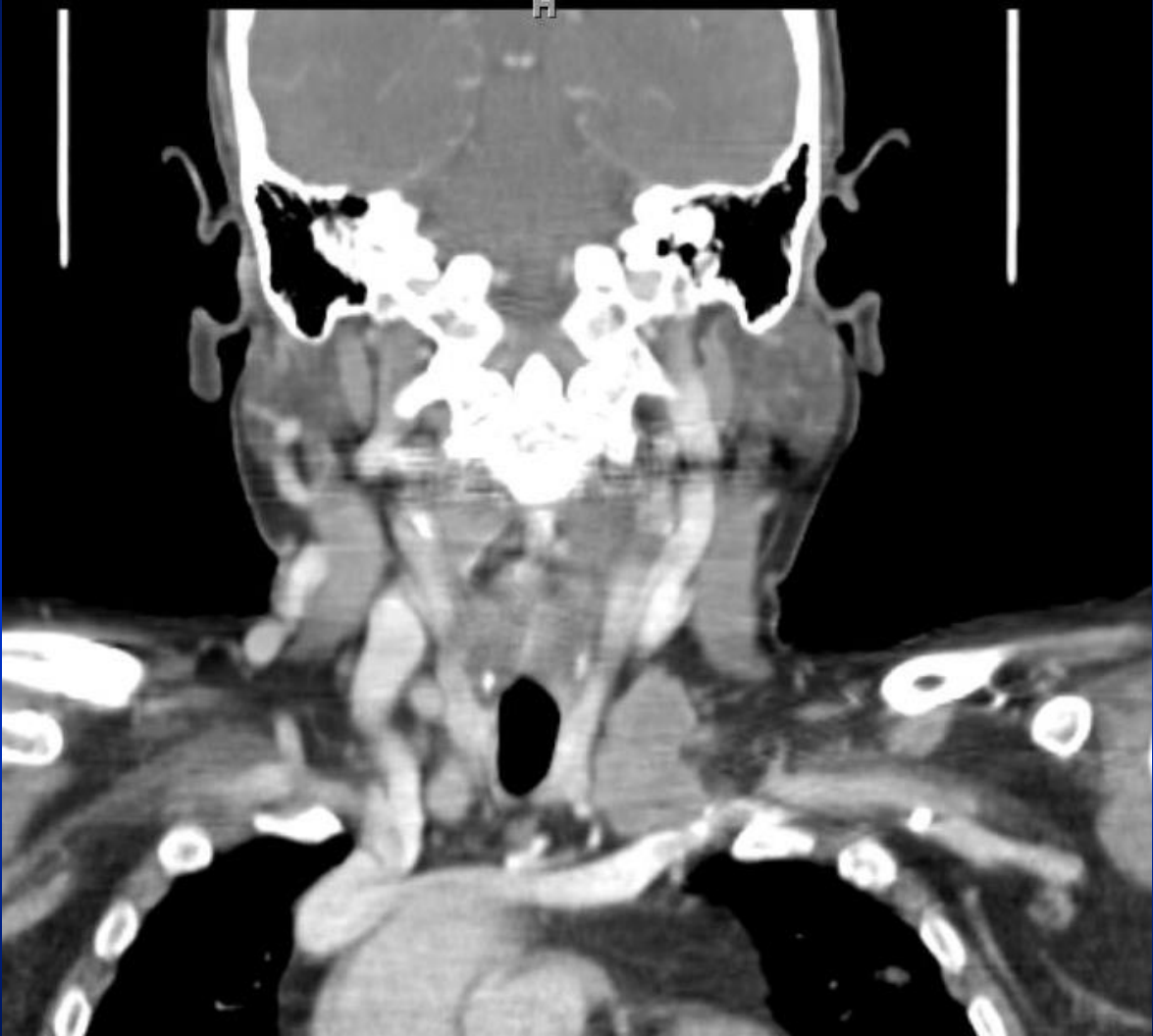6. How do you decide if and how much ^{131}I to administer?
7. What are your criteria for recommending external beam radiation for locally advanced PTC?
8. Do you incorporate information about *BRAF* mutation or do you only rely upon clinical and pathological presentation?

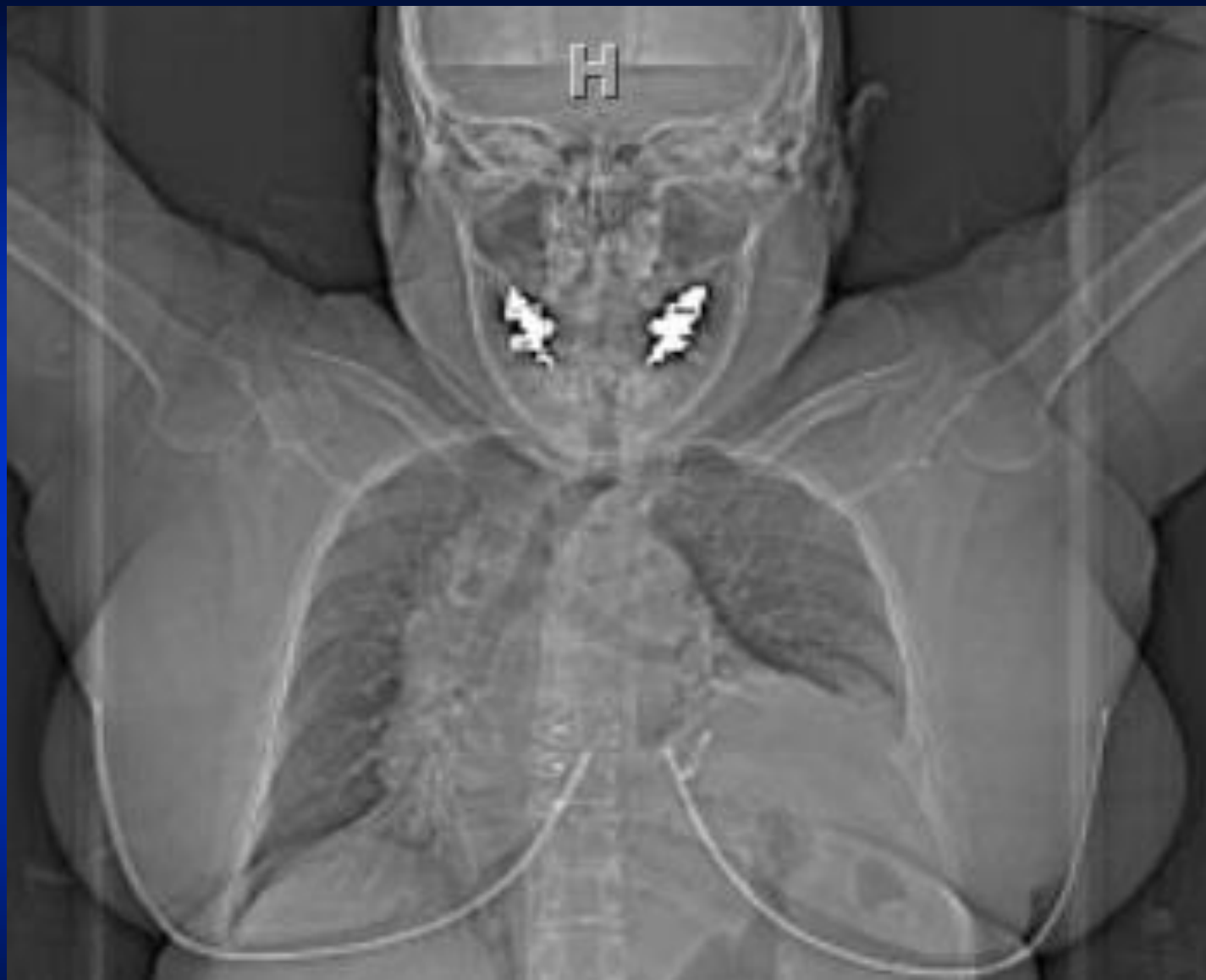Case #2

On 11/2009: 64 yo woman presented to the emergency room with shortness of breath.

CT scan revealed pulmonary nodules, left supraclavicular Level IV lymphadenopathy, 7x8x6mm ill-defined left thyroid nodule, and paralyzed left hemi-diaphragm.

FNA of supraclavicular mass; metastatic PTC





Questions: Case # 2

1. How concerned are you with a phrenic nerve paralysis? The carotid appears free of tumor invasion.
2. Are there additional tests you would require?
3. Would you consult other subspecialty surgeons such as a vascular surgeon?

The patient underwent total thyroidectomy, central and left modified radical neck dissection. The lateral nodal mass involved phrenic nerve, vagus nerve, internal jugular, carotid artery. Resected with transection and re-anastomosis of carotid artery.

Postoperatively the patient had a unilateral vocal cord paralysis; thoracic duct leak that was repaired first postoperative day

T3N1bM1 Tall cell variant of PTC; multifocal with extra-nodal extension

Questions: Case # 2

1. If you have unexpected small area of involvement of the carotid artery how do you approach it intra-operatively?
2. How do you avoid injury to the thoracic duct and how do you manage it once recognized postoperatively; do you have a drainage cutoff before intervening surgically?
3. Should she receive I¹³¹, external beam radiation, adjuvant tyrosine kinase or VEGF inhibitors?

The patient received 100 mCi I¹³¹ treatment

Tg 0.3 with TSH 72 uIU/ml; pulmonary metastases with negative Tg Ab

7/2010 left temporal metastasis

Resection of a 1.4 cm left temporal metastasis and stereotactic radiotherapy of 1600 cGy

Rx: multi-targeted receptor tyrosine kinase (RTK) inhibitor;
Sunitinib

Questions: Case # 2

1. Could you comment on stereotactic radiotherapy?
2. Could you comment on the indications for Sunitinib?

9/2011 The patient died from complications of recurrence of supraclavicular mass and brain metastasis 2 yrs after her initial surgery.

Case #3

A 77 male from Ethiopia presented with progressive right-sided neck swelling. Ultrasound revealed a 5.4 cm mass in the right thyroid lobe, nodularity in left thyroid lobe and right lateral neck lymphadenopathy. The patient complained of voice changes.

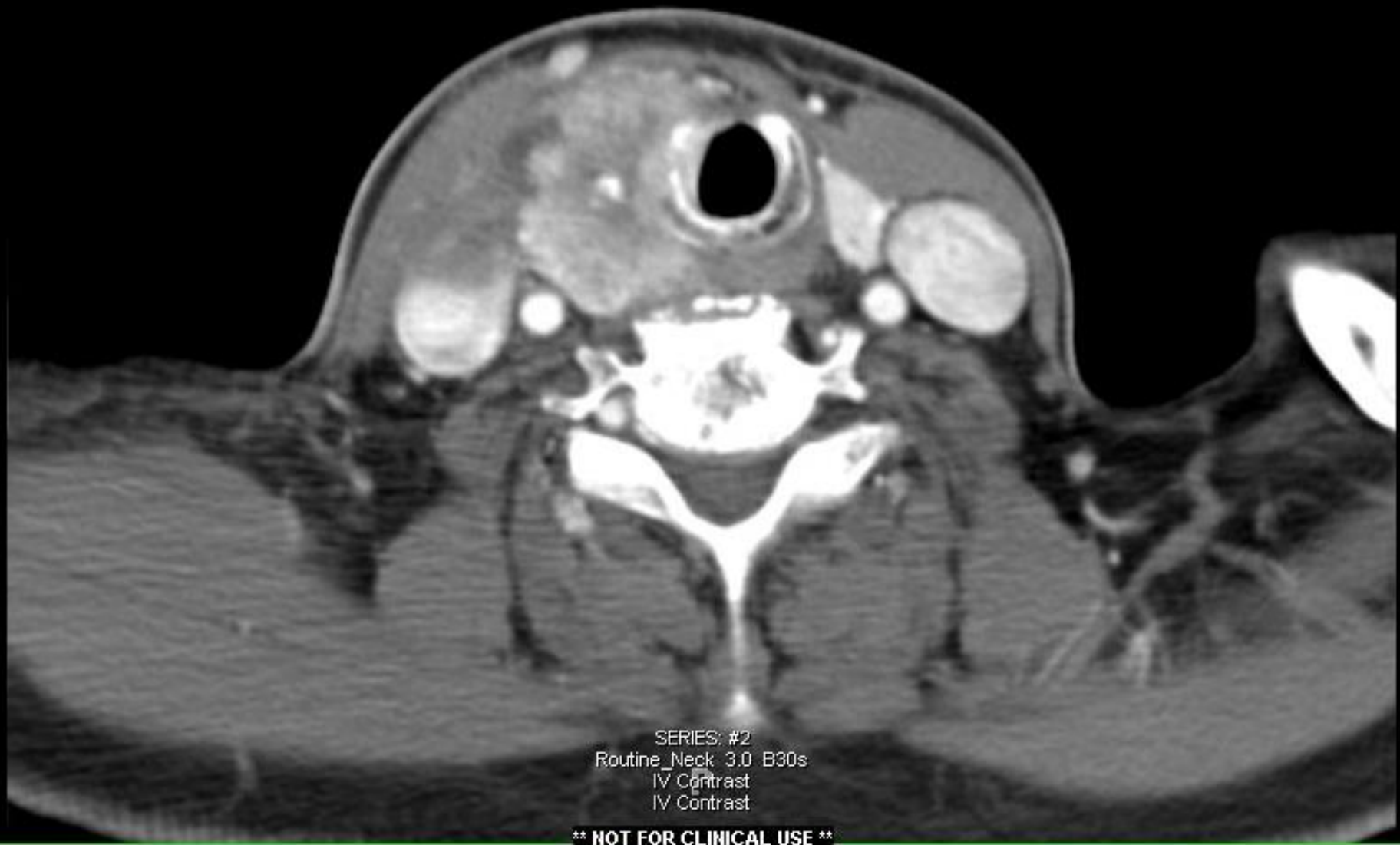Denied FH of thyroid cancer or Hx of irradiation exposure

Evaluation:

FNA: PTC

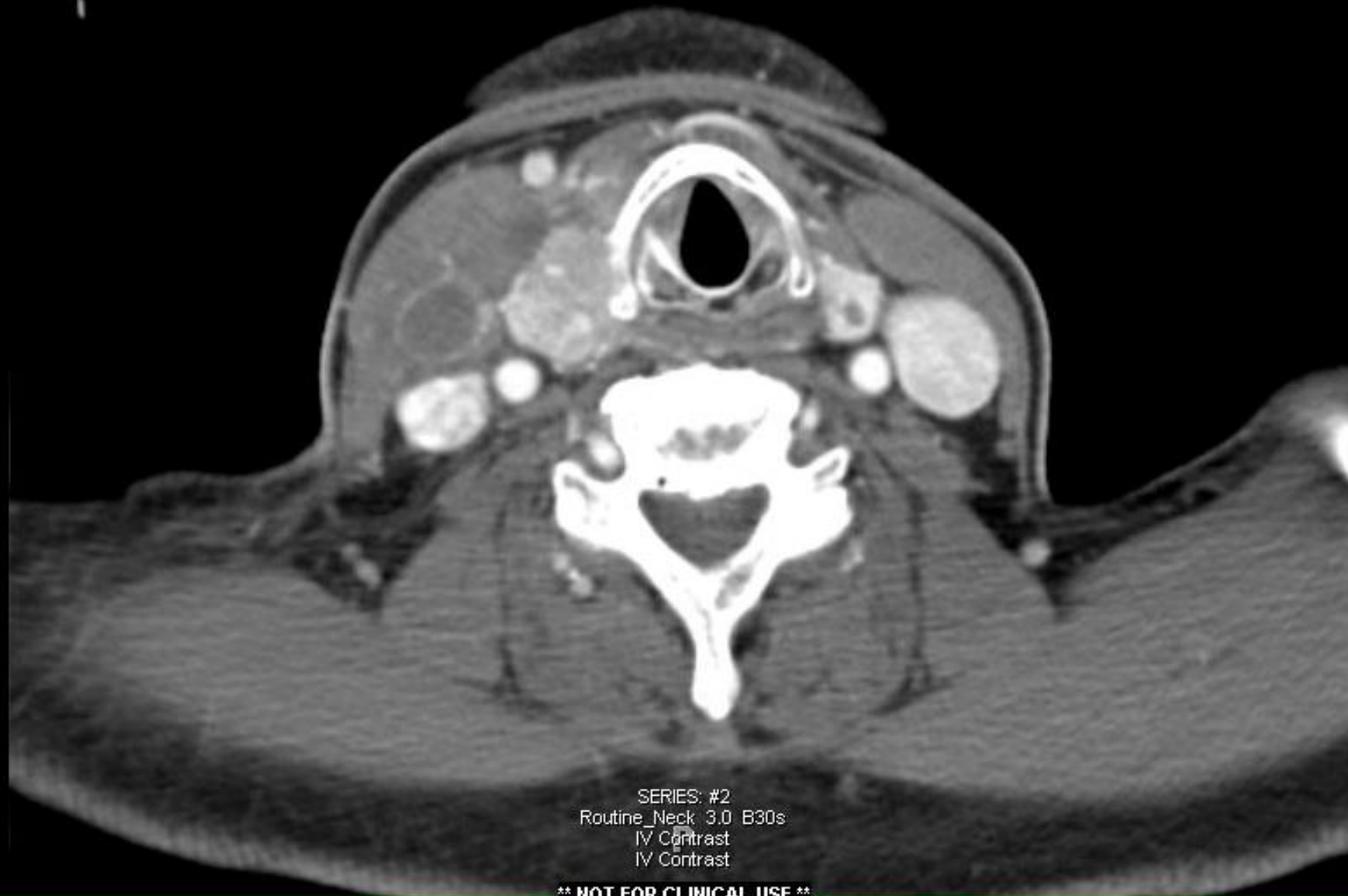Fiberoptic laryngoscopy: right true vocal cord paralysis

CT scan showed mass 4.4 x 3.4 cm extending into both thyroid and cricoid cartilage on the right, encircling ½ airway at the level of cricoid; invasion of cricoid and inferior aspect of laryngeal cartilage; loss of fat planes in trachea-esophageal groove; invasion of strap muscles; right vocal fold deviated medially; tumor involving the right lateral wall of esophagus; lymphadenopathy right levels II-IV and mediastinum; multiple subcentimeter pulmonary nodules



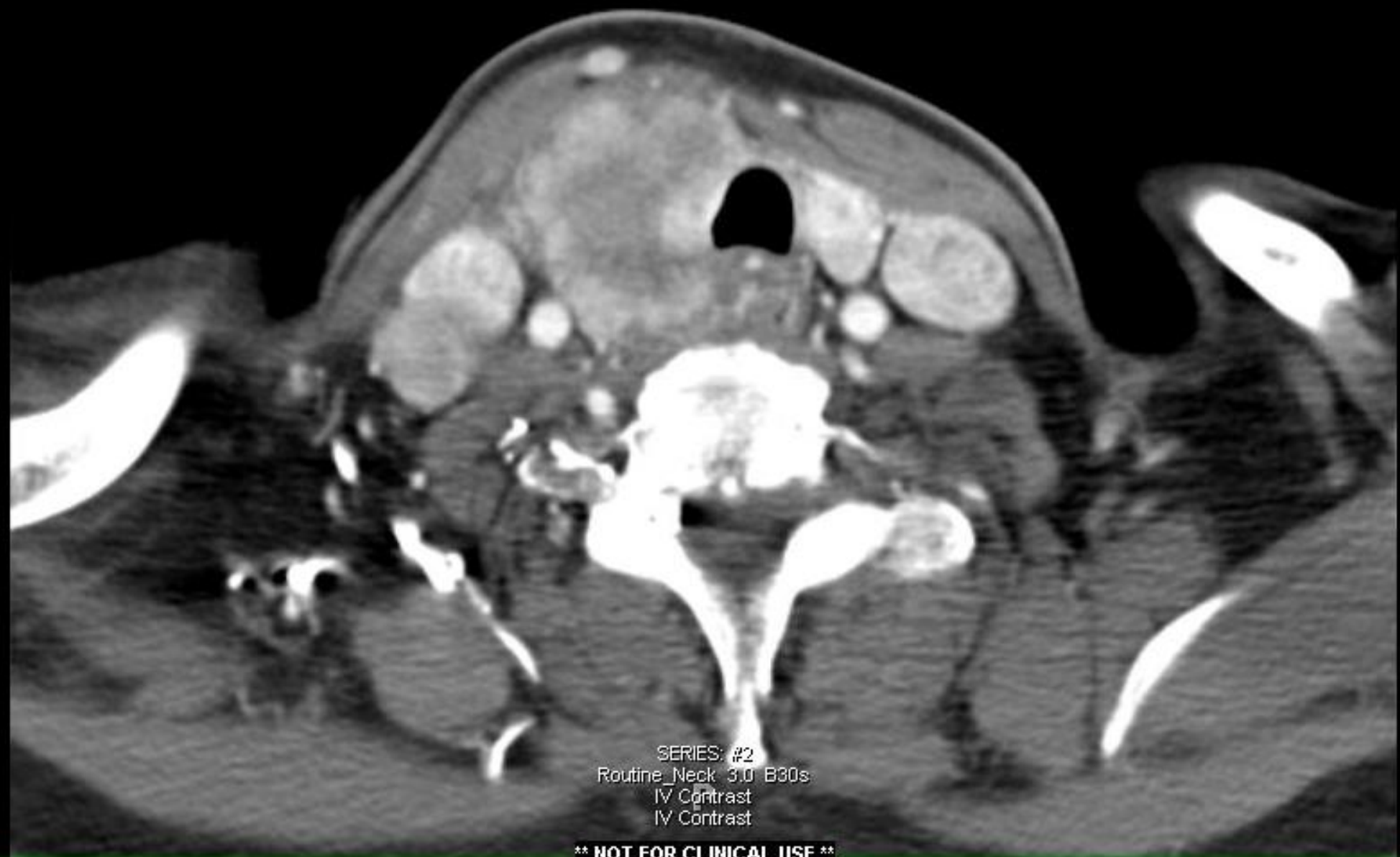SERIES: #2
Routine_Neck_3.0_B30s
IV Contrast
IV Contrast

**** NOT FOR CLINICAL USE ****



SERIES: #2
Routine_Neck 3.0 B30s
IV Contrast
IV Contrast

**** NOT FOR CLINICAL USE ****



SERIES: #2
Routine_Neck 3.0 B30s
IV Contrast
IV Contrast

**** NOT FOR CLINICAL USE ****

Questions: Case # 3

1. Do you evaluate the vocal cords on every patient regardless of symptoms?
2. What criteria do you use to determine whether or not the tumor is resectable?
3. Can you comment on your approach to resecting adjacent larynx, trachea, and reconstruction?

Surgery: total thyroidectomy with tracheal resection; bilateral CLND and RMRND; right RLN sacrificed; defect involving anterior half of cricoid, and 2.3 resection of 5 tracheal rings below; total 7 cm in length

Trachea mobilized off esophagus; larynx mobilized from hyoid; substernal trachea mobilized and advanced; remnant attachment of trachea from cricoid; trachea rotated about 180 degrees; advanced trachea superiorly and larynx inferiorly; multiple stay sutures around tracheal rings; 2 mm wire passing burr used to drill holes in thyroid ala; remnant cricoid and trachea closed; sternohyoid rotated over suture line; tracheostomy and Dobhoff tube placed

Pathology: 5cm PTC with positive margins 10/29 lymph nodes positive
T4N1bM1

Questions: Case # 3

4. What adjuvant therapy would you recommend; I¹³¹, external beam radiation, *BRAF* inhibitor? How do you decide upon a treatment scheme?

- Rx: 100 mCi I¹³¹ & radiation Rx to 60Gy of radiation
- 9/2008 Tg 22.6 ng/mL
- 7/2010 Tg 29.1
- 2/2011 Tg 51.0
- 3/2012 Tg 123.3
- 3-19-13 Tg AB 39; Tg 183 ng/mL; TSH <.02 uIU/mL
- 3-13: CT scan of chest and neck: Significant increase in size of pulmonary nodules with soft tissue fullness in left thyroid bed increased since last CT scan

Questions: Case # 3

5. Another dose of I^{131} ? Addition of protein kinase inhibitors?

Questions from the audience?