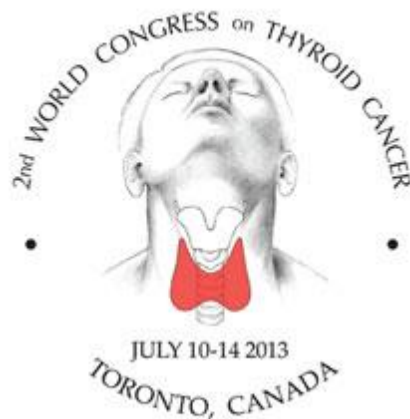

# Hot Topic Discussion #1

## *Non-Surgical Ablative Treatments for Thyroid Nodules and Thyroid Cancer*



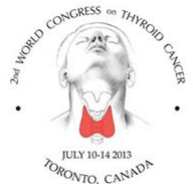**2<sup>nd</sup> World Congress on Thyroid Cancer**

an international meeting on thyroid cancer and nodules

**July 10-14, 2013**

# Disclosures

- None relevant to this presentation



# Panelists

- **Roberto Valcavi, MD**
  - IRCCS Santa Maria Nuova
  - Reggio Emilia **ITALY**
- **Giovanni Mauri, MD**
  - IRCCS Policlinico San Donato
  - Milano, **ITALY**
- **Nobuhiro Fukunari, MD, PhD**
  - Showa University Hospital, School of Medicine
  - Yokohama Northern Hospital
  - Yokohama, **JAPAN**



# The Plan...

1. Laser, RF and HIFU in benign nodules - Valcavi
2. Laser in LN metastasis - Mauri
3. RF & laser in 1<sup>0</sup> microPTC - Fukunari/Valcavi
4. Cases/Q&A





# Case 1

- **1997**
  - 66 yo ♂, 4 cm PTC, TT, I<sup>131</sup> (100 mCi)
- **2013**
  - 82 yo
  - two left supraclavicular/zone IV LNs (1.0 cm and 0.6 cm)
  - ↑ Tg - undetectable to 6
  - FNA + PTC

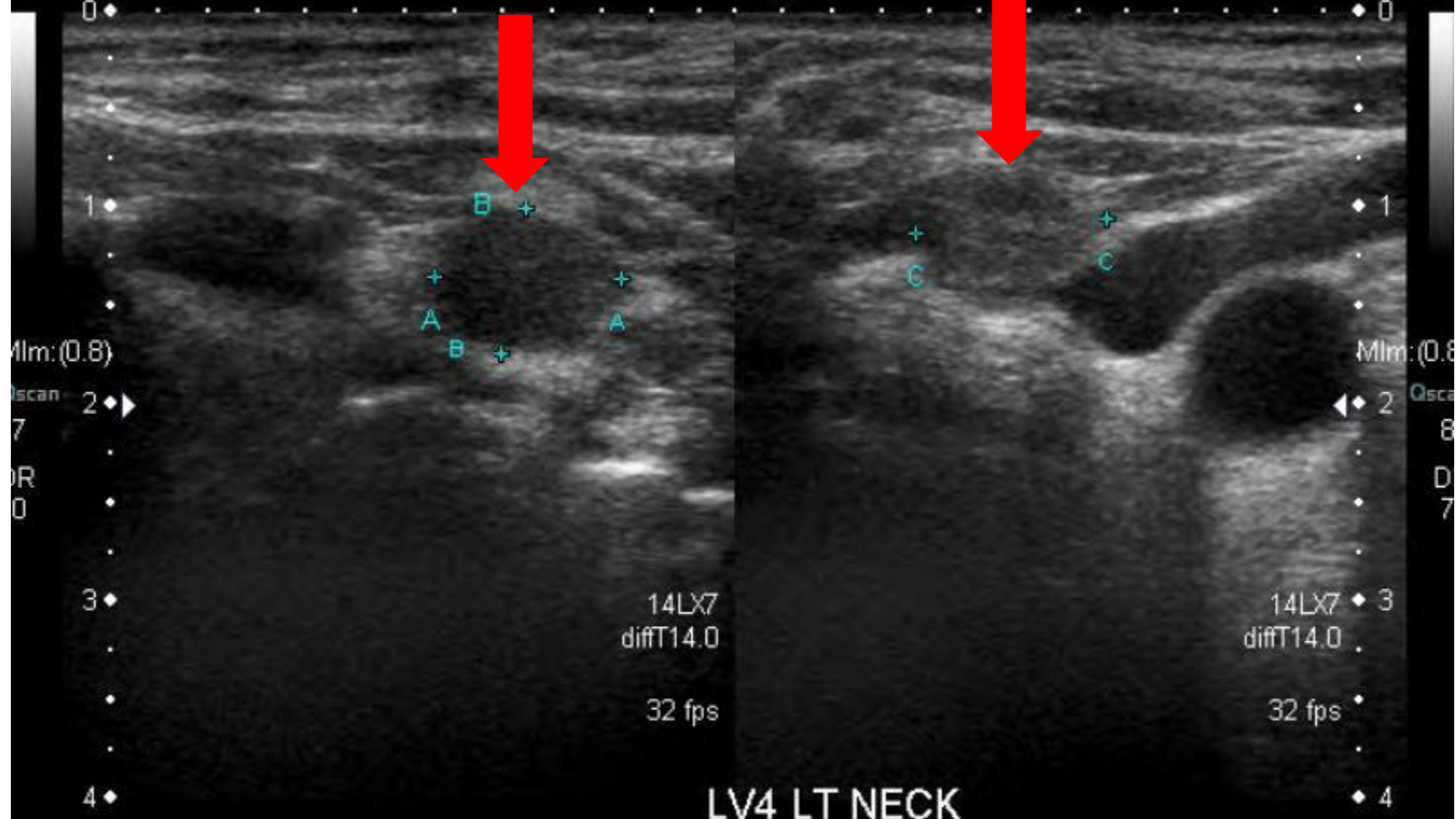


LOSSY

QPure

T

QPure



LV4 LT NECK

Dist A	9.5 mm	Dist B	7.5 mm	Dist C	9.7 mm	#6	#153
--------	--------	--------	--------	--------	--------	----	------



LOSSY

QPure

1



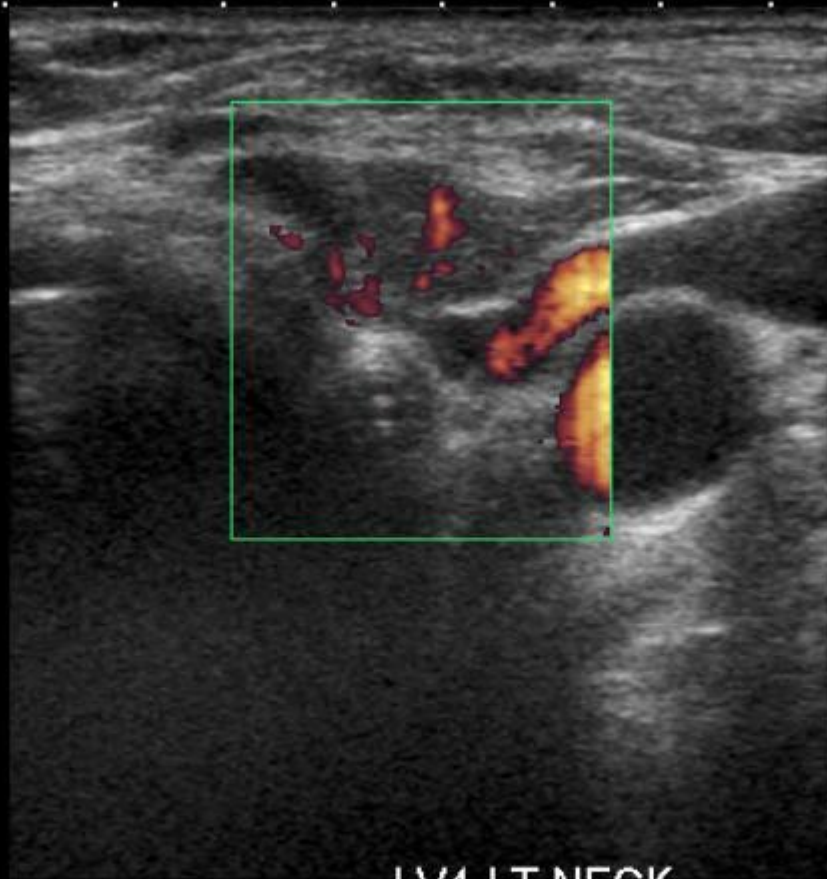0

1

2

3

4

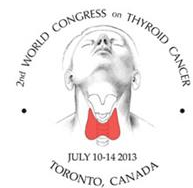

4LX7  
iffT14.0  
CF 7.2  
fps

MIm: (1.8  
Qsca  
8  
D  
7  
C  
4  
PR  
7.8  
Filt

LV4 LT NECK

#7



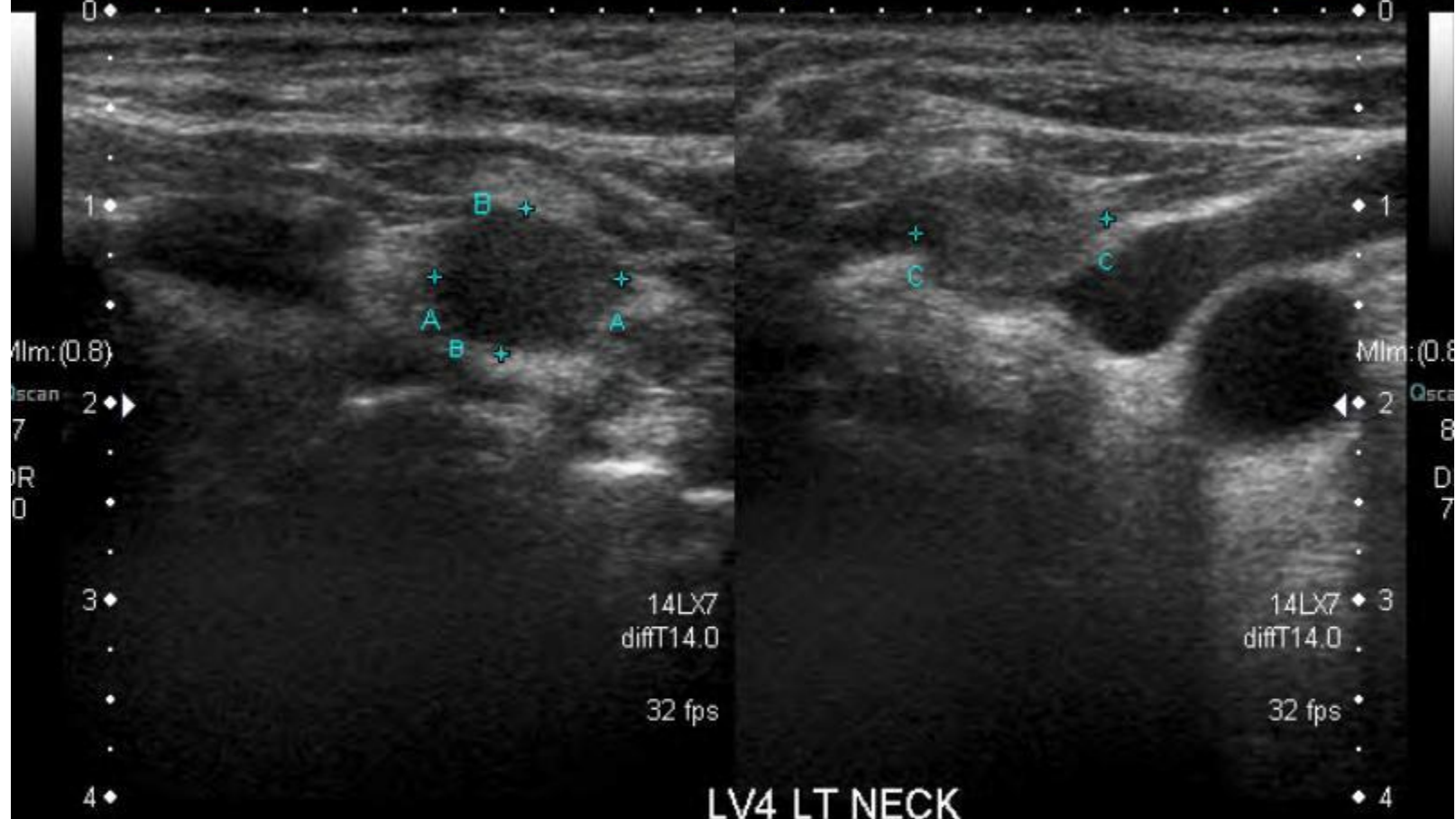


LOSSY

QPure

T

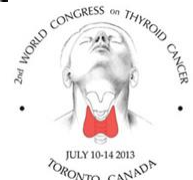QPure



Dist A	9.5 mm	Dist B	7.5 mm	Dist C	9.7 mm
--------	--------	--------	--------	--------	--------

#6

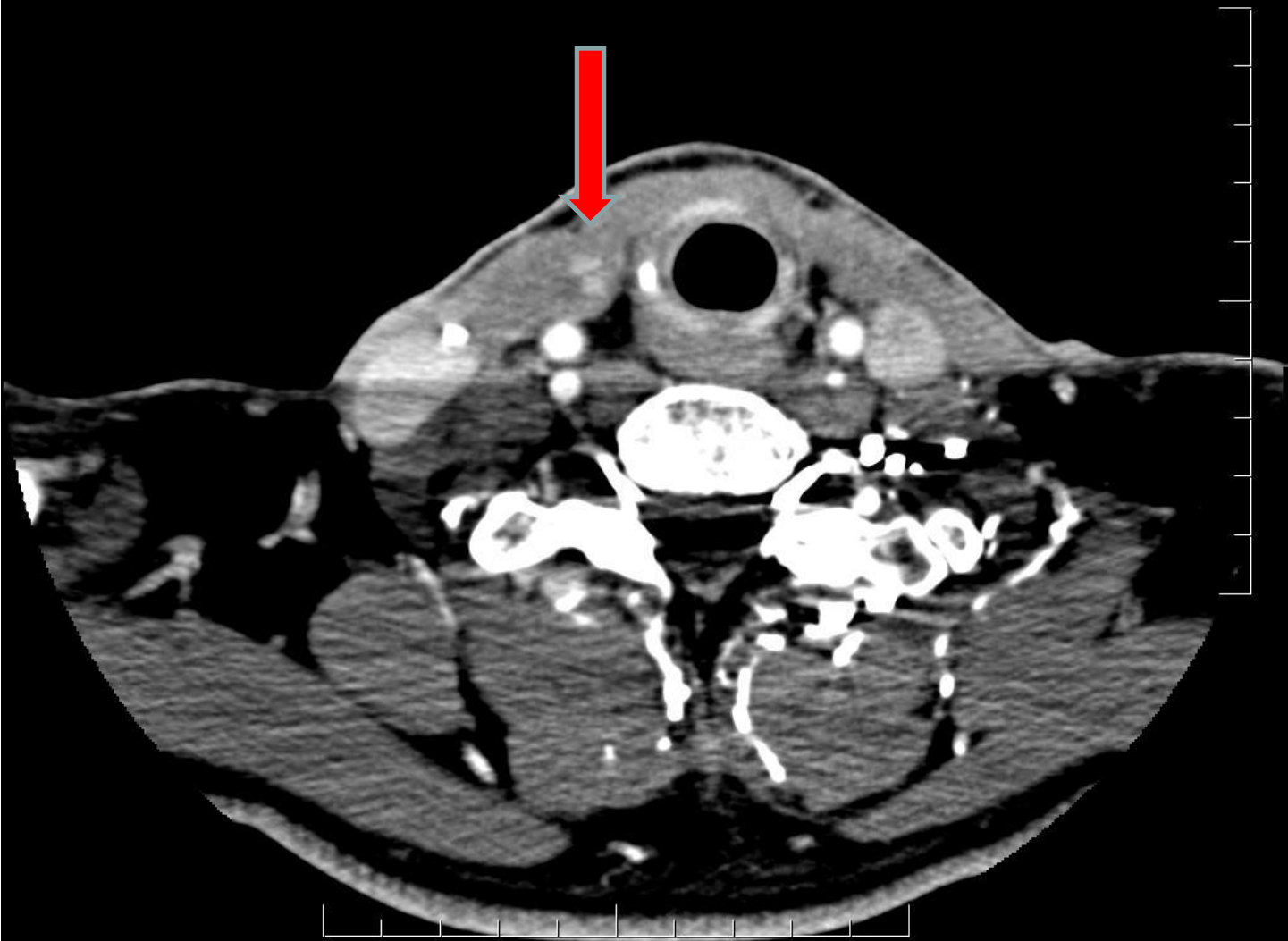
#153

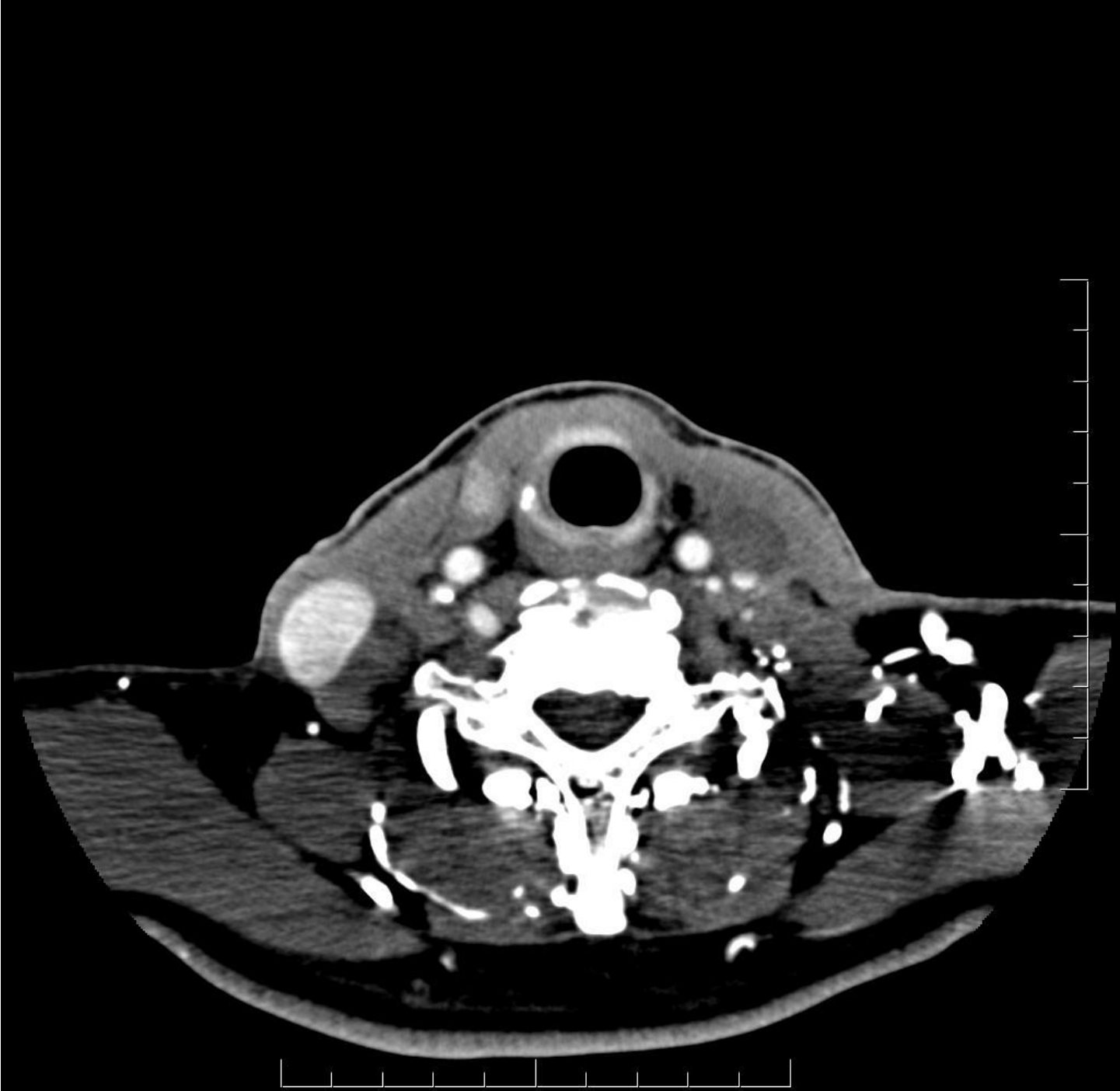


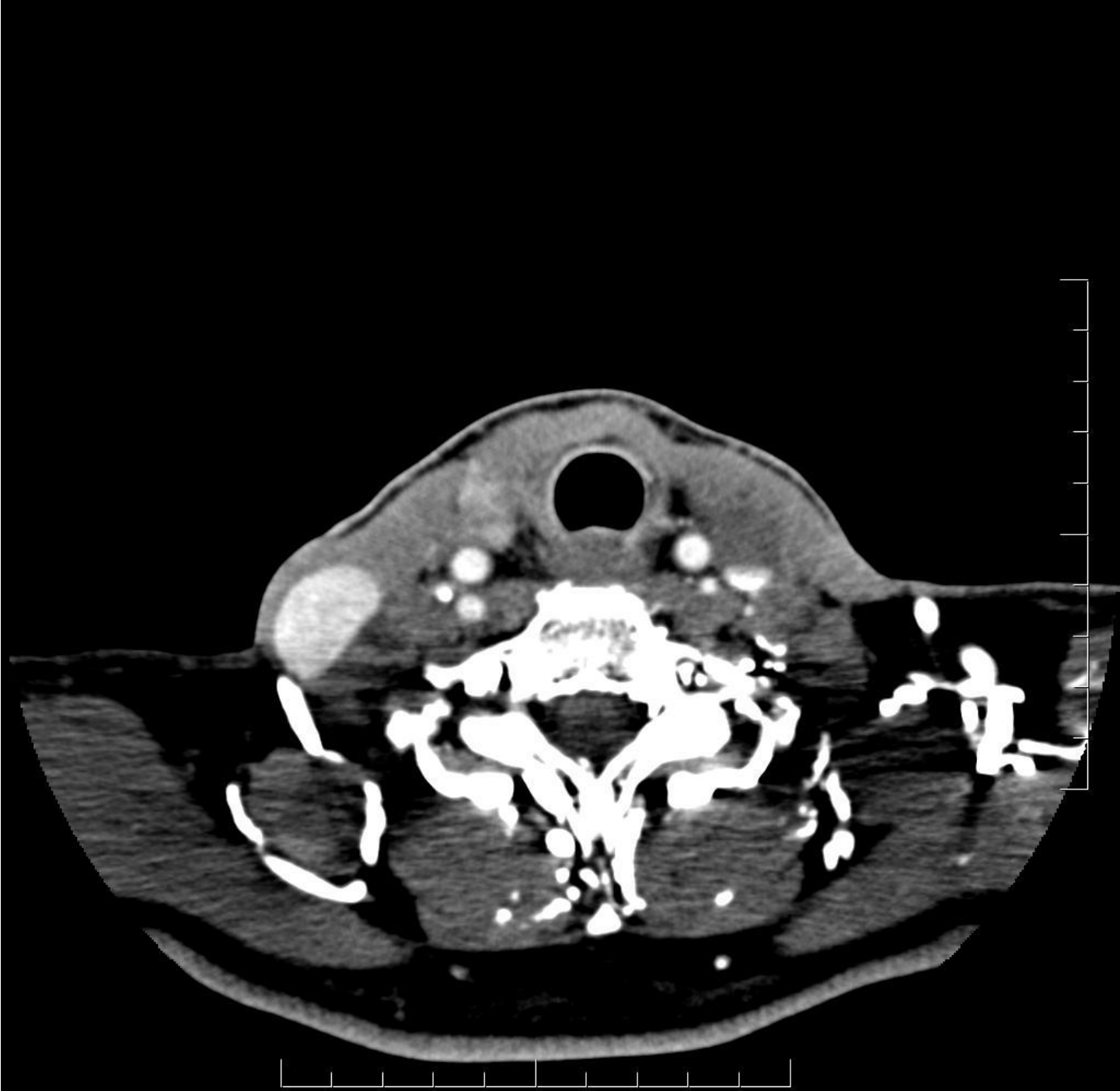# Case 2

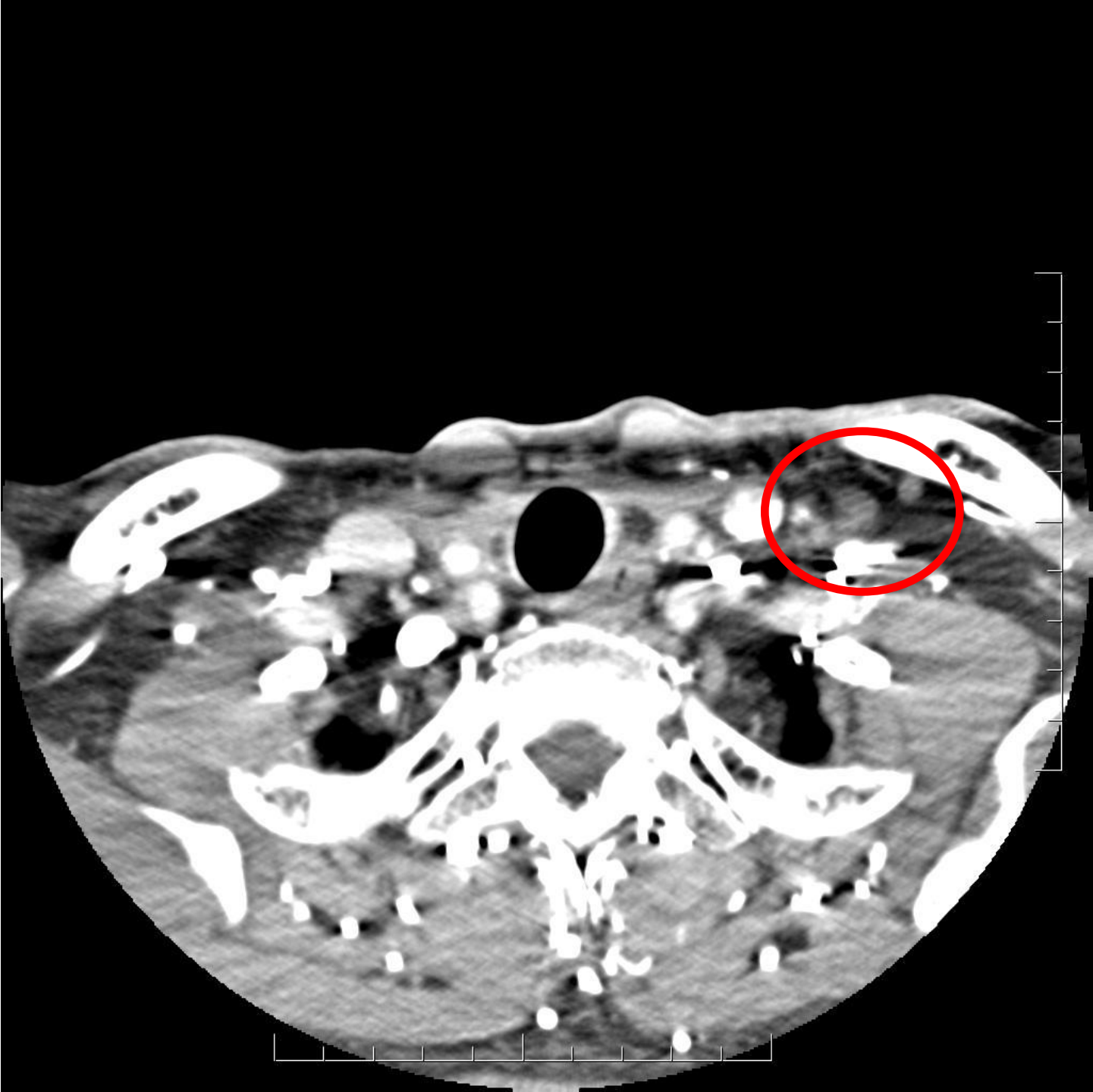
- 1999 – TT + I<sup>131</sup>, 3.5 cm pap Ca
- 2002 - ↑ Tg (53) – I<sup>131</sup>
- 2006 - Bilat ND (II-Vb), CND, 6+/152
- 2013
  - Right thyroid bed mass (0.8 to 1.9 cm), two supraclavicular LNs (0.8 cm, 0.9 cm)
  - ↑ Tg – 2 to 5
  - FNA + PTC, R thyroid bed mass

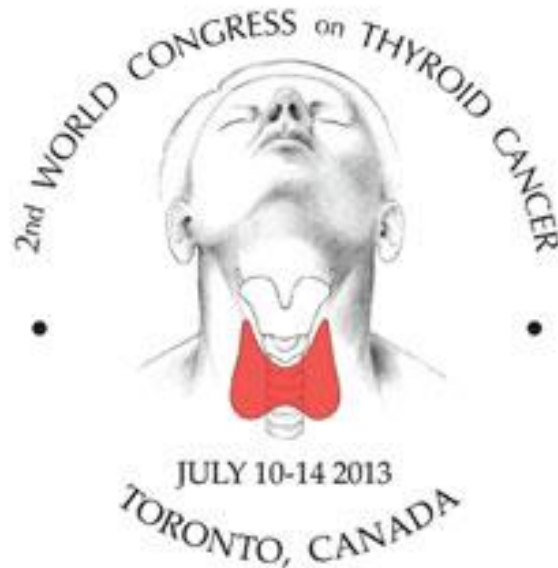











# **2<sup>nd</sup> World Congress on Thyroid Cancer**

an international meeting on thyroid cancer and nodules

**July 10-14, 2013**